

Pitbull Mauling Deaths in Detroit

Cheryl L. Loewe, MD, Francisco J. Diaz, MD, and John Bechinski, DO

Abstract: Between the years 1987 and 2005, there were 6 deaths reported in Wayne County, Michigan, associated with pitbull dog attacks. This article discusses the age incidence, scene investigation, nature of the injuries, and discussion relative to fatal dog attacks, an unusual accidental type of death.

Key Words: mauling, pitbull, fatal dog bite
(*Am J Forensic Med Pathol* 2007;28: 356–360)

The following 6 cases from the Wayne County Medical Examiner's Office in Detroit, Michigan, involve accidental blunt force injuries sustained in fatal pitbull dog attacks. The findings seen at autopsy, in general, consist of multiple lacerations, sets of puncture wounds, and extensive scalp avulsions, primarily sustained to the head and neck region of the body, which result in extensive mutilating injuries to the body and death results from exsanguination. There is a tendency for these animals to attack the neck region and destroy the blood vessels of the neck and cause extensive avulsions of the scalp and ears. In the majority of the cases, the victims were children or elderly. Four of the victims were children (age range 2 months to 6 years), 1 victim was a middle-aged adult (age 44), and 1 victim was an elderly adult (age 91). Three of the victims were male and 3 of the victims were female. Three of the victims were white and 3 of the victims were black.

MATERIALS

The following 6 cases of death caused by pitbull mauling are presented, which were all investigated and autopsied between the years 1987 and 2005 at the Office of the Wayne County Medical Examiner, Detroit, Michigan. A thorough scene investigation and a complete autopsy with documentation of external and internal injuries were performed in all cases. Complete toxicological screening was performed on all cases. In some cases, the animal(s) involved in the attack were shot and the gastric contents were recovered from the

dead animal. The cases will be discussed in sequence in an order according to increasing age.

CASE REPORTS

Case 1

A 2-month old white male infant was found decapitated on the living room floor. A 12-year-old sibling was sleeping on the sofa in the same room and awoke because the baby was crying. The infant was attacked by the family pitbull, who was previously stray and recently acquired by the family. Autopsy revealed decapitation with bite marks surrounding the ragged tissue margins on the neck. The dog was destroyed and examination of the gastric contents revealed multiple fragments of bone, skin and soft tissue, the nose, 1 globe, and both ears of the infant. Toxicology was negative (Figs. 1A and 1B—ref. case 9589-87—black and white photographs).

Case 2

A 1-year-old white male child was placed on the kitchen floor by his 54-year-old grandmother, who was babysitting the child. The grandmother stepped out of the room momentarily and returned to find the child being attacked by the family pitbull. The salient autopsy findings include multiple lacerations and sets of puncture wounds to the face, neck, and arms. Extensive scalp and facial avulsions were also present. Internally, there was a puncture wound to the right internal jugular vein. The animal forcefully attacked the neck region of the body, causing fracture dislocation of the vertebral spine at the level of C7–T1. There were also punctures, lacerations, and crushing injury to the larynx. Toxicology was negative (Figs. 2A, 2B, 2C, and 2D—ref. case 04-3275—images 11, 19, 21, and 28).

Case 3

A 1-year-old male child was attacked while playing in the front yard of his home by 2 pitbull dogs who were roaming the streets freely. The mother had stepped inside the home briefly to answer the telephone and saw her son being attacked through the window.

Autopsy revealed a large gaping hole in the right side of the neck with numerous puncture wounds to the right main carotid and right jugular vein, the esophagus, and trachea. The entire back was covered by scratch marks and puncture wounds. Multiple lacerations were present on the face, the chest, and the groins. Toxicology was negative (Fig. 3—ref. case 93-8688—kodachrome).

Manuscript received January 30, 2006; accepted June 28, 2006.
From the Office of the Wayne County Medical Examiner, Detroit, Michigan.
Reprints: Cheryl L. Loewe, MD, Office of the Wayne County Medical Examiner, 1300 E. Warren, Detroit, MI 48207. E-mail: cloewe@co.wayne.mi.us.
Copyright © 2007 by Lippincott Williams & Wilkins
ISSN: 0195-7910/07/2804-0356
DOI: 10.1097/PAF.0b013e31815b4c19

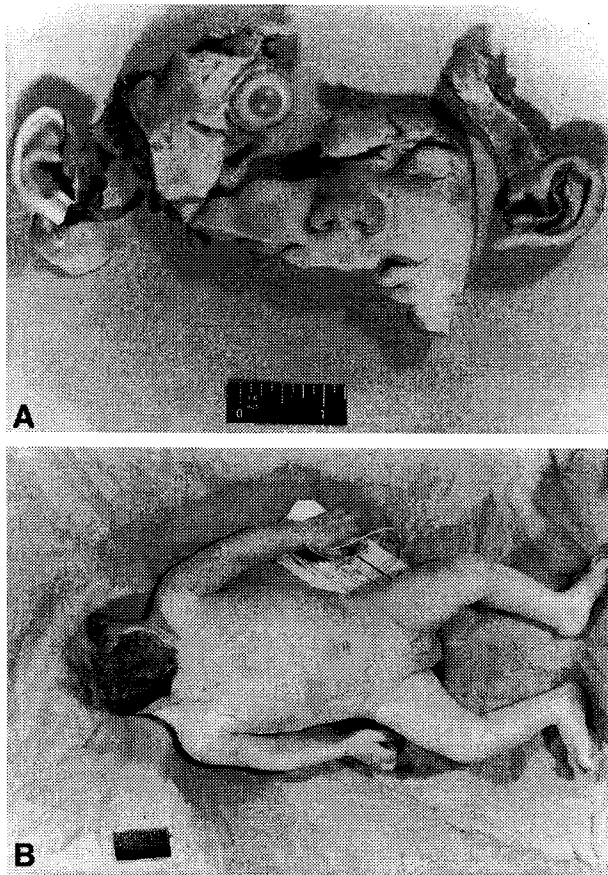


FIGURE 1. A, Partially reconstructed face recovered from dog stomach. B, Decapitation.

Case 4

A 6-year-old black female child was walking to school in an alley adjacent to her backyard. The family was in the process of moving to a nearby neighborhood and the 2 family pitbulls had just been set free after being locked up in the basement before the incident. The child grew up with these 2 pitbull dogs. Both dogs, who were roaming loose in the backyard, attacked the child in the alley and dragged her into the backyard of the dwelling. The child's pantyhose and skirt were pulled down below the knees. The mother of the child attempted to pull the dogs off of her daughter and called her husband for assistance. The police arrived and shot the dogs. The child was accidentally shot by police gunfire in the back of the knee. Autopsy examination revealed numerous lacerations, puncture wounds, and avulsions to the face and neck, 67 in total. Brush burn abrasions consistent with drag marks were also present. Neck dissection disclosed complete transection of the left common carotid artery. In addition, there were multiple skull and facial fractures with evidence of blood aspiration in the lungs. Multiple fragments of skull bone were absent and/or separately received with the body, including the left orbit and the left maxilla. A superficial gunshot entrance wound involving soft tissue was also

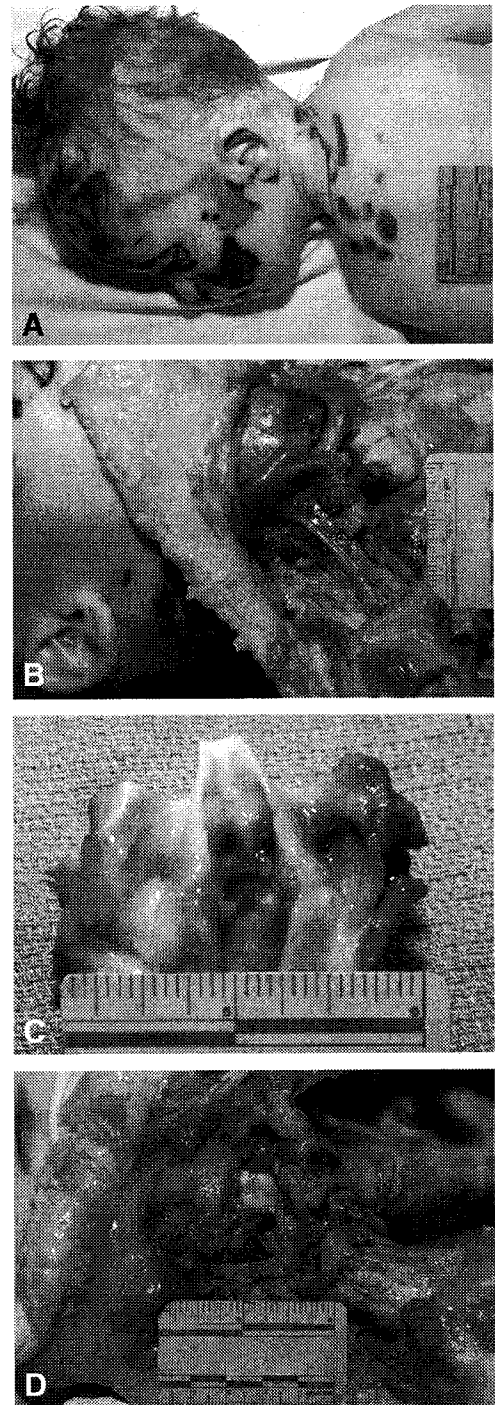


FIGURE 2. A, Lacerations: Face, neck, and back. B, Perforation neck blood vessels. C, Puncture wounds on larynx. D, Fracture of vertebral spine.

demonstrated on the back of the right knee and a bullet was recovered from the wound track. Toxicology was negative (Figs. 4A and 4B—ref. case 3365-05—images 5 and 15).

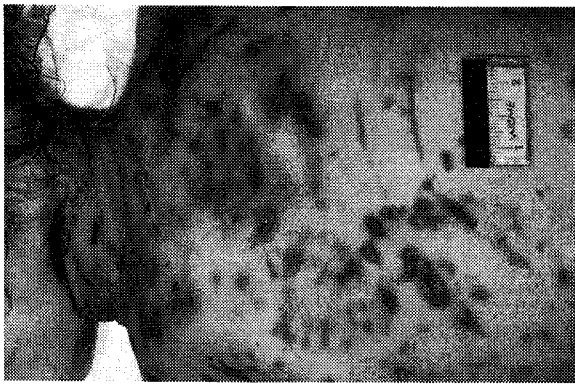

FIGURE 3. Lacerations and abrasions, neck and back.

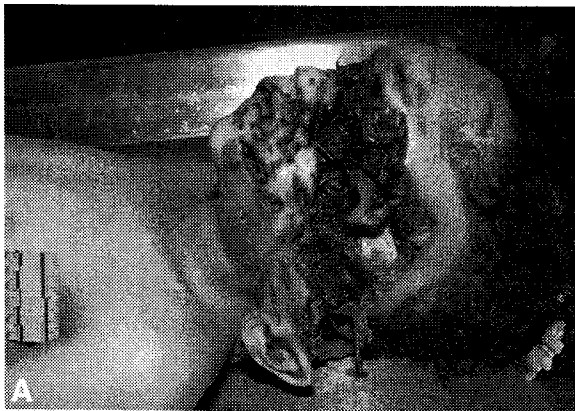


FIGURE 4. A, Lacerations, face. B, Gunshot wound on the leg.

Case 5

A 44-year-old black woman was attacked by 2 pitbulls who resided at an occupied dwelling while walking down the street. The subject was observed laying on the ground and 1 dog was attacking the neck region of the victim, while the other dog was attacking her lower back. A citizen notified the police who arrived and shot the animals with their service weapons. Autopsy revealed multiple clusters of abrasions, deep lacerations, and puncture wounds distributed over the face, the front and back of the neck the arms, the lower back,

and the legs. There was complete avulsion of the left ear and partial avulsion of the right ear. Extensive scalp avulsions were also noted. There was complete transection of the left brachial artery, the left basilic vein, and the right common carotid artery. There was a bone defect in the T1 vertebra and dislocation of the first right rib. Toxicology revealed a post-mortem blood ethanol of 0.11 g/dL (no figures available).

Case 6

A 91-year-old black woman was attacked by her own family pitbull dog at home. The autopsy revealed multiple extensive scalp avulsions, 1 measuring 5 inches in diameter on the back of the head with exposure of the calvarium and deep undermining pockets of subgaleal hemorrhage. Numerous lacerations were present on the eyes, both cheeks, the mouth, the lower face, the left upper neck, both ears, and the left side of the head. Many paired puncture wounds were noted consistent with animal teeth. Two of the lacerations on the face were deep and associated with absence of the lip, skin, facial muscle and soft tissue, right maxilla, and zygoma, resulting in exposure of the sinuses and oropharyngeal cavity. A closed right hip fracture was present. Internal examination revealed pale, bloodless viscera, blood aspiration in both lungs and comminuted fracture of the bilateral zygoma, bilateral maxillary bones, the palatine bone, and the right mandible with loss of several upper and lower teeth and laceration of the tongue. Toxicology was negative (Figs. 5A and 5B—ref. case 05-11440—images 14 and 4).

DISCUSSION

These cases presented demonstrate rather dramatic mutilating injuries sustained to the human body after pitbull attack. The common trend in the observable injuries include injury to the blood vessels and/or organs of the neck in all of the cases, resulting in exsanguination. Extensive scalp avulsions were also observed in most of the cases and the portion of avulsed scalp is unattached to the head and likely eaten by the animal. The patterned sets of puncture marks are another consistent finding compatible with the dentition of the animal (Fig. 6A—ref kodachrome—dog mouth—ref. case 93-8688). Scratch marks were noted in some cases and a comparison of these patterned injuries are consistent with the animal claws that inflicted them (Fig. 6B—ref. case 93-8688—dog paw). In 2 of the cases, the animal attacked forcefully enough to fracture and/or separate the vertebral spine. Complete decapitation injury was present in 1 case and the gastric contents recovered from the animal confirm that the soft tissue and bone are eaten by the animal. In half of the cases, there were fractures of the facial bones and/or calvarium. Avulsions or partial avulsions of the ears was another common finding. The majority (67%) of the victims were small children, those least likely to protect themselves. The same reasoning can apply to elderly victims.

The head and neck region of the child was at the level of the dogs teeth, making these anatomic regions more accessible to the dog during attack. Of the dog-mauling deaths of neonates in the literature, all occurred on the dog